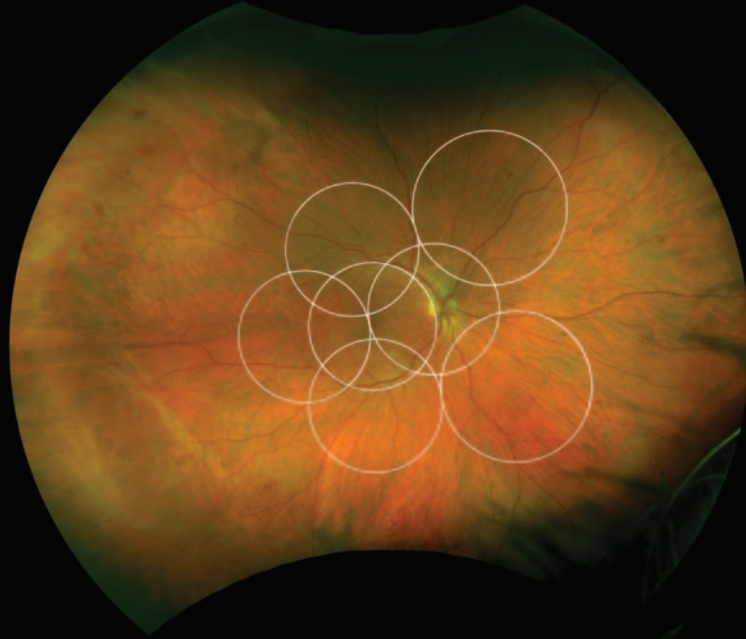

# optomap

## EQUIVALENT TO ETDRS



### Results from a large multi-center collaborative study confirm the equivalence of optomap® to ETDRS Gold Standard for grading diabetic retinopathy.

A newly published study on over 700 eyes at 38 sites demonstrated ultra-widefield (UWF™) imaging has moderate to substantial agreement when determining diabetic retinopathy (DR) severity within the area covered by Early Treatment Diabetic Retinopathy Study (ETDRS) 7-standard field<sup>1</sup>. The results of several previous clinical studies comparing **optomap**® UWF images have indicated that there is substantial agreement with ETDRS 7-standard film photographs and dilated fundus examination in determining diabetic retinopathy severity<sup>2,3</sup>.

When compared the **optomap** and ETDRS images agreed exactly 59% and were within one level 97% of the time. Predominantly peripheral DR lesions (PPL) were present in 41.0% of these eyes and suggested increased DR severity by 2 or more steps in 11.0%. Whether identification of these peripheral lesions will substantially impact the ability to predict risk of future DR progression awaits final data from this ongoing study<sup>1</sup>.

*“The identification of a subset of eyes at greatly increased risk of DR progression and onset of PDR that cannot be assessed by ETDRS 7-field imaging would have significant implications for the evaluation and care of diabetic eye disease. Not only would UWF devices be the preferred imaging modality, but their use would be important in clinical trial settings requiring precise prediction of DR progression rates, in clinical care for accurate patient counseling, and in tele-ophthalmology programs to improve risk assessment and triage in eyes that otherwise would not have the peripheral retina evaluated.”*

*Ophthalmology 2018*

See how **optomap** will help you manage your diabetic patients. For more information call **800-854-3039** or email **BDS@optos.com**



A Nikon Company



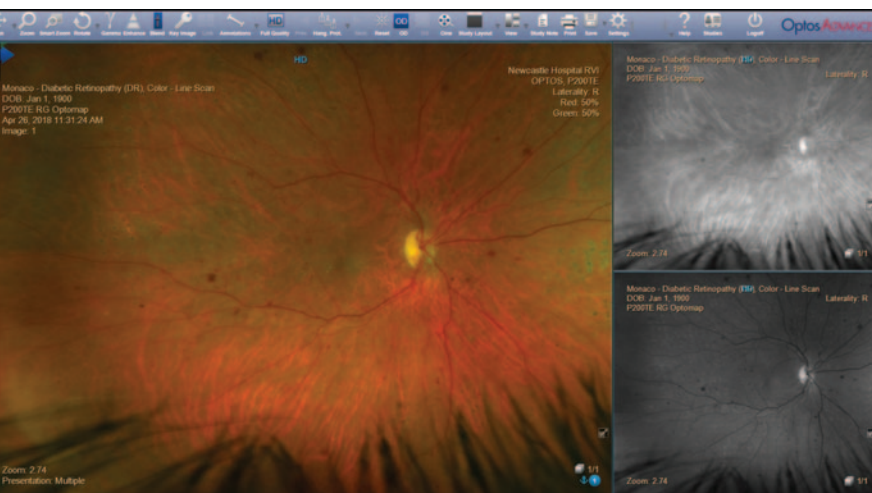
Building **The** Retina Company

# CLINICAL SUMMARY

## Can Ultra-widefield Retinal Imaging Replace ETDRS for Grading Diabetic Retinopathy?

For two decades, the standard for determining severity of DR has been the extended modified Airlie House classification used in the ETDRS study where the location and extent of specific retinal lesions on 7 stereoscopic pairs of fundus photographs are evaluated in the posterior pole. The identification of these lesions was highly correlated with the risk of progression. Previous studies have reported on the value of UWF imaging for the identification of DR lesions in the retinal periphery<sup>2,3,4</sup>.

This study reports the evaluation of ETDRS and UWF for the grading of DR in a large multi-center (38 sites) collaborative group. 385 patients with nonproliferative diabetic retinopathy (NPDR) (ETDRS retinopathy severity level 35-53), no history of panretinal photocoagulation, and no central-involved diabetic macular edema on OCT were enrolled in the study.



optomap images can be evaluated using OptosAdvance for DR lesions as a color composite image or the image can be separated into red and green channels to improve the visualization of individual lesions.

- This study demonstrates that ETDRS and UWF imaging have moderate to substantial agreement when determining DR severity within the central pole and that UWF imaging can be used in place of ETDRS imaging for DR grading and management.
- Images were evaluated by independent masked graders for DR severity.
- There were 737 gradable eyes on both the UWF masked and ETDRS images after adjudication, 435 (59.0%) eyes had exact agreement and 714 (96.9%) were within 1-step.
- Predominantly peripheral DR lesions (PPL) were present in 41.0% of these eyes and suggested increased DR severity by 2 or more steps in 11.0%.
- UWF images were better for assessing DR level in 27% of eyes than ETDRS.
- UWF imaging in clinical settings not only increases the frequency of diabetic retinopathy identification nearly 2-fold, but also reduces acquisition time by more than half, ungradable image rate by 71% (to <3%) and reduces image evaluation time by 28% compared to nonmydriatic fundus photography<sup>4</sup>.
- Future findings from the longitudinal data from this study might provide a definitive answer as to whether the use of UWF images can improve methods to assess and triage eyes at risk for DR worsening.
- Previous studies have found that PPL were associated with an almost 5 fold risk in the progression of diabetic retinopathy (DR) over 4 years<sup>5</sup>. The current study suggests that enough patients have PPL at baseline to answer this question at the conclusion of this trial<sup>1</sup>.

#### References:

1. Comparison of ETDRS Standard 7-field Imaging versus Ultrawide Field Imaging for Determining Diabetic Retinopathy Severity. JAMA Ophthalmology. 2018.
2. Nonmydriatic Ultrawide Field Retinal Imaging Compared with Dilated Standard 7-Field 35mm Photography and Retinal Specialist Examination for Evaluation of Diabetic Retinopathy. American Journal of Ophthalmology. 2012.
3. Peripheral Lesions Identified by Mydriatic Ultrawide Field Imaging: Distribution and Potential Impact on Diabetic Retinopathy Severity. Ophthalmology. 2013.
4. Potential efficiency benefits of nonmydriatic ultrawide field retinal imaging in an ocular telehealth diabetic retinopathy program. Diabetes Care. 2014.
5. Peripheral Lesions Identified on Ultrawide Field Imaging Predict Increased Risk of Diabetic Retinopathy Progression over 4 Years. Ophthalmology 2015.



Optos plc  
Tel: +44 (0)1383 843350  
ics@optos.com

Optos, Inc.  
Call Toll-free (US & Canada): 800-854-3039  
Outside of the US: 508 787 1400  
usinfo@optos.com

Optos Australia  
Tel: +61 8 8444 6500  
auinfo@optos.com



CE  
0197